



Hologic Trident™ Specimen Radiography System

Improving Margin Clearance and Increasing Operating Room Efficiency

The Use of the Hologic Trident™ Specimen Radiography System in Improving Margin Clearance and Increasing Operating Room Efficiency

*Edibaldo Silva, MD, PhD, Associate Professor of Surgical Oncology,
University of Nebraska Medical Center, Omaha, Nebraska*

This paper is one in a series of research overviews on advanced technologies in women's healthcare. For copies of other white papers in the series, please contact: womenshealth@hologic.com.

Introduction

Almost 80 percent of women diagnosed with early-stage breast cancer in the United States are candidates for breast conservation surgery (BCS); yet sadly, the percentage of women who chose a mastectomy is increasing steadily.¹ This is due in large part to confusion among patients and physicians not conversant with the recommendations by the NCI Consensus Conference in 1991, (now buttressed by more than 30 years of clinical data), that BCS is equivalent to mastectomy in every measure and should be the preferred approach because it is associated with fewer physical and emotional complications. Advances in systemic hormonal therapy, chemotherapy and radiation therapy have made recurrence rates comparable in both groups. Among women choosing BCS, as many as 50 percent undergo a mastectomy due to the presence of a microscopic residual tumor at the margin of the lumpectomy specimen, leaving the not always confirmed possibility of a tumor left behind. Thus, it behooves the breast surgeon to minimize the likelihood of positive margins at BCS to avoid a subsequent mastectomy.

Among the most common reasons for positive margins is the eccentric position of a non-palpable or palpable cancer within the lumpectomy specimen. Over the past eight years, I have used two-dimensional intraoperative specimen mammography to assess the circumferential gross margins of surgical specimens. For the past year, I have utilized the new Hologic Trident™ specimen radiography system in over 80 cases to address the question of potential positive margins intraoperatively. This is in an attempt to replicate our previously reported advantages of margin clearance using intraoperative two-dimensional specimen mammography with careful specimen orientation.

The Trident system localizes the closest gross margin given the location of the actual tumor, biopsy clip marker or micro-calcifications within the lumpectomy specimen. In this manner, one can empirically re-excise any potentially close gross margin at risk. We aim to obtain a 1-2 cm gross margin with the expectation that the likelihood of microscopic disease discovered at final pathology will be low.

This paper addresses the impact of the Trident specimen radiography system on our ability, using radio-guided lumpectomy, to improve margin clearance, increase staff and operating room efficiency, and reduce the number of mastectomies we perform on women who prefer breast conservation surgery.

Reducing Re-excisions

The most common cause of positive margins is the inability to identify the location of the cancer within the lumpectomy specimen during the initial breast conservation surgery. While the standard of care during surgery is to obtain a 2 mm microscopic clear margin uniformly around the cancer, the eccentric location of a cancer within the lumpectomy specimen will often result in a positive or close margin.

The Trident system provides us a very accurate method of localizing the cancer within the lumpectomy specimen and predicting the likelihood of a positive margin. We are able to do this effectively when micro-calcifications are the target, as in ductal carcinoma in situ (DCIS), because the resolution and contrast of Trident images are much higher than comparable systems or standard mammography equipment. Our two-dimensional images are obtained without specimen compression and thus provide a true representation of the specimen and the cancer within it. The Trident system uses Hologic's selenium-based direct conversion detector technology, which eliminates light diffusion, providing clear, high-resolution images. This is the same technology Hologic uses in its digital mammography and breast tomosynthesis systems.

We use a Trident system in our operating room to take a two-dimensional image of the carefully marked and oriented specimen within seconds of removing it. The system is easy to use and images are available instantly, so that if the cancer is grossly less than 1-2 cm from any margin on the Trident grid, we know exactly which margin that is and re-excise it in the same sitting.

The Trident system maximizes the likelihood that pathologists will not find any cancer at the margins because we excise an average of 1-2 cm gross margins in all directions. While the standard of care is a microscopic 2 mm margin around the cancer, our goal is a gross margin on the Trident images with the expectation that a grossly clear 2 cm distance significantly reduces the likelihood of a positive microscopic margin.

Orienting Margins

With the Trident system, we carefully orient the specimen in two dimensions as soon as it is removed, and mark it so that our pathologists know which are the 12, 6, 3 and 9 o'clock positions, and what is front and back. If perchance our pathologists, who have the images in front of them while staining the specimen, report a positive margin on final hematoxylin and eosin (H&E) stains, it is a very carefully localized margin. We can reassure patients that we can get all of the cancer with a second lumpectomy, while taking more tissue only in the area with the positive margin and minimizing the potential cosmetic impact of a re-lumpectomy.

Consult Intraoperatively with Radiologists in Remote Locations

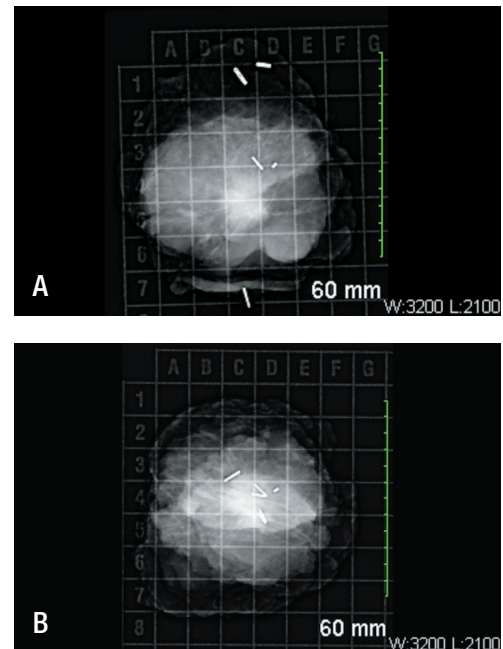
Locating the Trident system in the operating room has enabled us to reduce the time required for each BCS by an average of 25 minutes. Image capture is extremely fast and the images are available to evaluate on the spot. The Trident system eliminates the need to send the specimen out of the operating room to a mammography department elsewhere in the hospital. With the push of a button, I can send the image to a SecurView[®] diagnostic workstation in pathology and to our hospital PACS system, so that our mammographer can review the specimen and consult with me while I am still in the operating room. If I need to take more tissue, I do it during the initial surgery; the patient doesn't have to come back for a re-excision. When four or five cases are scheduled, one can save significant hours of staff and operating room time. Lastly, the Hologic images serve as proof that the Iodine-125 seed, which we use for radio-guided lumpectomy instead of wire localizations, has been explanted from the patient and retrieved by pathology for safe disposal.

Conclusion

The Hologic Trident specimen radiography system provides the high-resolution images we need in the operating room to accurately assess potentially close margins and re-excise these during the initial breast conservation surgery.

The Trident system's high contrast images let us look inside the specimen to see exactly where the cancer is located and to visualize peripheral micro-calcifications at risk, helping guide the decision to remove more tissue or to give confidence that the existing specimen is sufficient.

Over the past year, the Trident system has enabled us to dramatically reduce repeat operations for re-excisions and to provide our patients the successful and cosmetically pleasing breast conservation surgery they desire. With the Hologic Trident system, we are providing better patient care, a better operative result, and we are increasing the efficiency of our team.



BREAST IMAGE SHOWING CENTERED CANCER WITH CLEAR GROSS MARGIN OF ~2 CM AROUND THE REGION OF INTEREST

(A) An anterior-posterior view with the three marker clips clustered in the center of the specimen along with the biopsy clip and the Iodine seed for localization. (B) The same specimen turned 90 degrees. The front of the specimen has one single clip (anterior margin) and you see a sliver of the skin we included as the anterior margin). The two clips at the opposite edge represent the posterior margin.

Dr. Edibaldo Silva is a full-time surgical oncologist with a busy practice in breast cancer and general surgical oncology at the Olson Center for Women's Health at University of Nebraska Medical Center.

¹ <http://www.radiologyinfo.org/en/info.cfm?pg=breastcancer>

WP-00063 Rev. 001 Hologic, SecurView and Trident are trademarks and/or registered trademarks of Hologic, Inc., and/or its subsidiaries in the United States and/or other countries. Views and opinions expressed herein by third parties are theirs alone and do not necessarily reflect those of Hologic. This information is intended for medical professionals in the U.S. and other markets and is not intended as a product solicitation or promotion where such activities are prohibited. Because Hologic materials are distributed through websites, eBroadcasts and tradeshows, it is not always possible to control where such materials appear. For specific information on what products are available for sale in a particular country, please contact your local Hologic representative or write to womenshealth@hologic.com.

Hologic, Inc.
35 Crosby Drive
Bedford, MA 01730 USA
T: 781.999.7300
www.hologic.com
womenshealth@hologic.com