

An Evaluation of the Hologic® Celero® Vacuum Assisted Handheld Device for Ultrasound Guided Breast Biopsies

Brian S. Englander, M.D., Pennsylvania Hospital

This “white paper” is one in a series of research overviews on advanced technologies in women’s healthcare.

For copies of other white papers in the series please contact womenshealth@hologic.com

Introduction

The primary goal of minimally invasive breast biopsy techniques is to reduce the amount of time, cost and trauma associated with surgery as a diagnostic procedure without sacrificing histological accuracy. Over 1 million women undergo surgical procedures each year to diagnose an abnormality found during mammography.¹ Over the past decade, ultrasound-guided (US) large-core needle biopsy has become a reliable and acceptable alternative to surgical biopsy for the classification of breast lesions.^{2,3,4} The benefits of minimally invasive breast biopsies can be further extended through the utilization of a device that not only replaces unnecessary surgical procedures but also produces a sufficient but not excessive number of samples that ensures an accurate histological assessment.^{4,5,6}

Typical spring-loaded core (SLC) and vacuum-assisted breast biopsy (VABB) devices, while established as acceptable alternatives to surgery, possess various limitations that require physicians to retrieve a considerable number of cores in order to be confident the samples reflect the true nature of the lesion. Perhaps combining the advantageous features of SLC and VABB devices can help reduce the number of core samples required for an accurate diagnosis.

Reducing the number of core samples is of little value unless concordance between imaging and biopsy diagnoses can be confirmed via the “triple test”. Based on this test, a surgical biopsy should be performed if discordance exists between the clinical, imaging or pathology results.² Physicians must be confident that their chosen modality can produce sufficient results. If concordance cannot be achieved, patients will be forced to undergo excisional biopsies, despite physicians’ efforts to avoid surgical procedures as a diagnostic tool.

Thus, a study was undertaken to investigate whether an ultrasound-guided biopsy device that combines features of traditional core biopsy methods can achieve concordance with just two samples.

History of Ultrasound-Guided Biopsy

Open surgical biopsy was the previous gold standard for the diagnosis of breast abnormalities. As research increasingly showed the use of large-core needle biopsy to be as effective as

surgical excision, the increased cost, greater risk of complications and the potentially adverse cosmetic results of an open surgical procedure made this option a less desirable diagnostic tool.⁷

Fine Needle Aspiration

Until a decade ago, the only alternative to a surgical biopsy was the use of fine-needle aspiration (FNA). However, FNA offers a low level of diagnostic accuracy, often producing false negatives, wrong diagnoses, or no diagnoses at all. In fact, studies show that FNA yields inconclusive results up to 29 percent of the time. FNA is also extremely operator dependent, requiring a high level of expertise unavailable in many areas. The major problem with FNA, however, is that it cannot distinguish between Ductal Carcinoma In Situ (DCIS) and infiltrating carcinoma.⁶

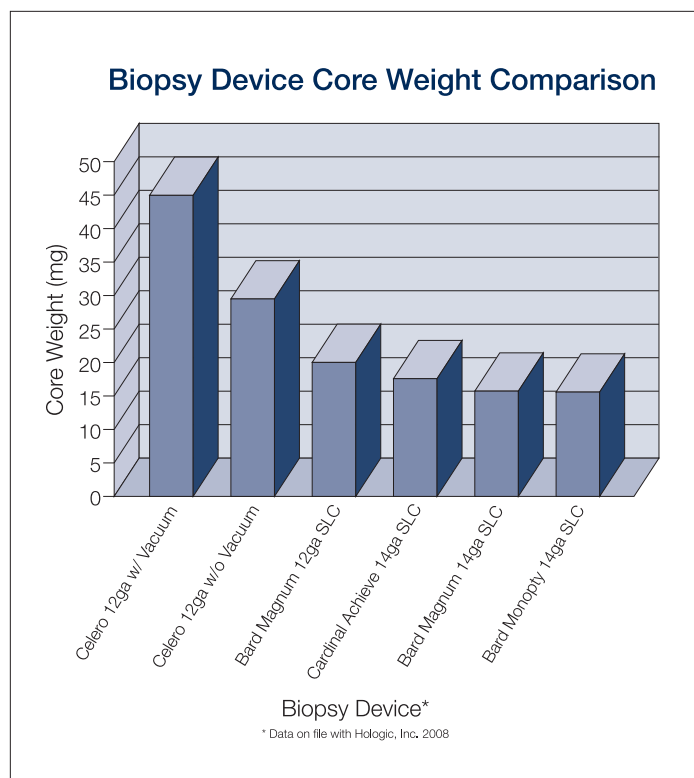


Figure 1. Core weights of commercially available SLC breast biopsy devices

Core Needle Biopsy

During the past 10 years, core needle biopsy proved to be a viable alternative to FNA. Both SLC and VABB devices provide physicians with a greater level of accuracy, as well as the ability to grade DCIS and differentiate it from infiltrating carcinoma. However, both types of devices are plagued with limiting factors of their own.

Most SLC devices require the physician to fire the needle inside the breast, minimizing directional control of the needle and making it difficult—and sometimes dangerous—for use in hard-to-reach areas like the axilla. In addition, most SLC devices utilize a small needle that typically requires a minimum of 5 or 6 cores to reach a diagnosis.² The more passes needed to achieve a sufficient number of cores, the longer the procedure time and the increased likelihood of breast trauma and patient discomfort.

VABB devices are favored for producing larger samples than SLC in ultrasound due to the vacuum assistance that holds tissue in place during acquisition. While VABB devices can be appropriate for benign removal of entire lesions, it is often an excessive procedure for simple diagnostic sampling. In particular, the large amount of tissue removed with vacuum-assisted devices puts patients at risk for developing hematoma. Many physicians also find the vacuum-assisted technique rather cumbersome, as the device must be attached to a large machine, making it difficult to use in the handheld biopsy arena where ultrasound technology is employed.

The Hologic Celero Handheld Device

The Celero device satisfies the need for a minimally-invasive breast biopsy device that can be inserted with the ease of a typical SLC device while producing the size of core samples usually associated with VABB. It is a handheld, disposable device that requires no capital equipment and is the first vacuum-assisted, spring-loaded core breast biopsy device for use in the ultrasound arena.

The Celero device utilizes a combination of features that enables physicians to acquire large cores more efficiently and consistently. These include:

- Vacuum assistance
- 12-gauge needle
- Pre-fire option to confirm aperture placement
- Trocar tip

Larger Cores

The Celero device's vacuum-assisted technology and 12-gauge needle yield cores that are significantly larger than other SLC devices (see Figure 1). The average weight of a core obtained with a 14-gauge SLC device is 17 mg, while the Celero device produces cores weighing approximately 45 mg. When

compared to a leading 14-gauge SLC device, the Celero device produces a core that was twice as large. The vacuum-enabled device consistently yields cores that are 2-3 times larger than the leading 14-gauge SLC devices.⁸ Yet as a handheld device it requires no capital equipment to operate, making utilization significantly easier than other vacuum-assisted technologies.

The Celero device's vacuum operates in a unique way that enables physicians to obtain large core samples without the limitations of other vacuum-assisted devices. Instead of aspiration created by a machine like other VABB devices, the vacuum is created by the device itself, similar to a syringe working in reverse. Pumping the device once closes the casing of the syringe. A second and third pump retracts the outer and inner cannulas, respectively. By depressing a button, the physician then fires the inner cannula; depressing a second button opens the outer section of the syringe and the vacuum is delivered to the aperture. This aspiration holds the tissue in place while the outer cannula is deployed, acquiring the tissue sample.

Pre-Fire Option

The Celero device allows the physician to pre-fire the inner cannula, enabling confirmation of aperture placement prior to tissue acquisition (see Figure 3), thus regaining the control lost with other SLC devices. Currently, the Celero breast biopsy device is the only FDA-approved vacuum assisted spring loaded core device with a pre-fire option. This device utilizes a 14-gauge needle; this small needle limits directional control in dense breast tissue making it difficult to image sonographically when placed deep within the breast.

Trocar Tip

The Celero device's trocar tip allows both inner and outer cannulas to fire in a straight line. Not only does this ensure that the device remains in a straight line during placement and firing, it also makes the device safe for skilled physicians to use in sensitive areas (i.e. axilla, chest wall, or near implants and/or the nipple). The trocar tip and rigid design of the inner cannula of the device guide the needle through the breast in a straight path even when traversing dense tissue.

Fewer Samples, Better Results

The larger, more contiguous samples obtained by the Celero device enable pathologists to more likely identify and classify malignant and benign breast tissue with greater accuracy. This requires fewer samples and fewer insertions in the breast.

Though five samples has been the accepted minimum for core needle biopsy, recent research demonstrates the ability to obtain fewer cores while achieving the same diagnosis.⁵ In a 13-year retrospective study that investigated the accuracy of detecting the presence of a malignancy when core needle biopsy diagnosed atypical ductal hyperplasia, results showed that

increasing the number of samples did not affect the accuracy of the diagnosis.⁹ Several studies suggest three or four core samples should be considered the minimum for an adequate histological assessment. However, the authors of these studies also conclude that in a majority of the cases, two samples were sufficient to obtain a clear and reliable diagnosis (see Figure 2).^{4,6} In a study of 144 patients and 150 masses, researchers found that although six cores were obtained, an increase in accuracy occurred by obtaining up to only two cores.⁵

If the features of the Celero device are found to allow physicians to confidently diagnose breast abnormalities using just two cores, it will prove to be an advancement over other core needle biopsy methods, like those used in the aforementioned studies; those devices did not improve accuracy beyond two samples but still required physicians to take as many as six in order to be certain concordance would be achieved. Thus, to compare the Celero device to traditional SLC modalities, a study was performed to measure whether two core samples taken with the device is sufficient to obtain a diagnosis that is concordant with imaging pathology.

Materials and Methods

Over a four month period (August-November 2007), US-guided biopsies utilizing the Celero device were performed on 38 lesions in 33 patients at Pennsylvania Hospital. Two cores were taken from each lesion. The first core was taken through the middle of the lesion, and the second core was taken from a different area. Additional cores, if needed, were to be taken and sent to pathology separately; however, no additional cores were required. The cores were placed in containers with labels identifying the order in which they were obtained, either first or second, and sent to pathology.

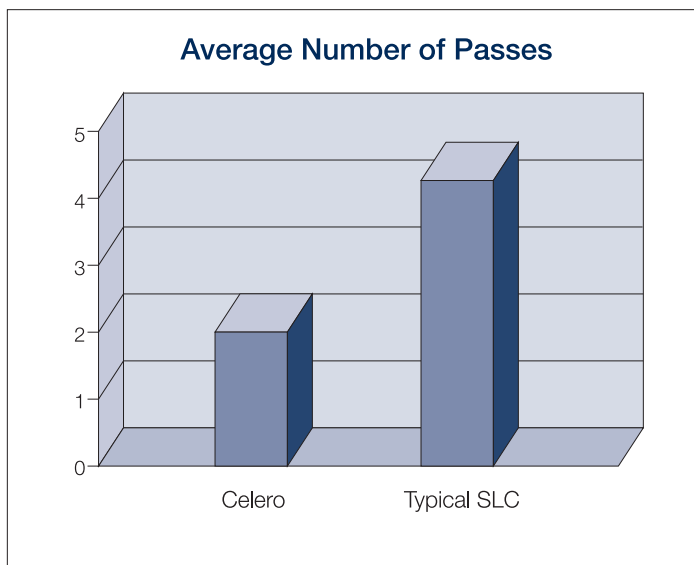


Figure 2. Average number of passes required with the Celero versus a typical spring loaded core device

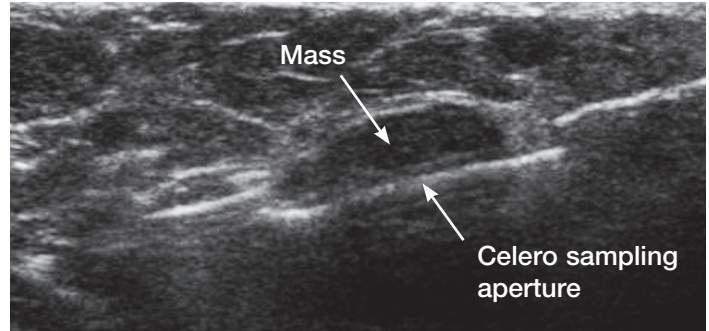


Figure 3. Ultrasound guided breast biopsy with the Celero handheld device using the pre-fire method for aperture confirmation

Before the procedure, patients were asked to complete a consent form. The physician documented anecdotal experiences for each procedure, including patient presentation, tissue type and lesion location, and then documented and compared experiences with the Celero device to those with an SLC device that would have typically been used. Patient follow-up included documenting whether the patient's condition necessitated surgery.

It should be noted that the physician was not compensated for participation in this research, including cost of the product.

Results

Two cores were obtained per lesion. Of the lesions, 29 (76 percent) were benign and nine (24 percent) were malignant. Of the malignancies, two (22 percent) were diagnosed as invasive grade 3 ductal carcinoma, three (33 percent) were infiltrating ductal carcinoma, two (22 percent) were infiltrating ductal carcinoma with DCIS present, one (11 percent) was metastatic carcinoma, and one (11 percent) was invasive lobular carcinoma. The length of the cores ranged from .1 cm to 2.7 cm.

Breast Biopsy Pathology Results

Benign	29
Invasive grade 3 ductal carcinoma	2
Infiltrating ductal carcinoma	3
Infiltrating ductal carcinoma w/ DCIS	2
Metastatic carcinoma	1
Invasive lobular carcinoma	1

Histological agreement between imaging and biopsy results was assessed, and concordance was achieved in 100 percent of the cases. Based on the physician's experience, only one out of the 38 lesions would have required just two cores if a SLC device had been used. An average of 4.26 cores would have been necessary with a SLC device, with as many as 5-6 cores in 40 percent of the cases.

The types of tissue ranged from primarily fatty replaced to extremely dense. Neither the type of breast tissue nor the lesion

location had an impact on the ability of the Celero device to achieve concordance while obtaining the minimum number of core samples.

Conclusion

The results of this study suggest the Celero handheld device is a vast improvement over other SLC devices given its ability to obtain a sufficient but not excessive number of core samples in order to make an accurate diagnosis. None of the cases included in the study required more than two tissue samples to make an assessment that was concordant with imaging pathology. A majority of lesions presented would have required 2-3 times the number of cores if a SLC device had been used.

This study supports the use of the Celero device as a preferred alternative to traditional SLC or VABB devices in order

to reduce the number of core samples, and thus the number of insertions in the breast, to achieve a sufficient histological assessment of breast lesions. By combining the advantages of its predecessors, the device enables physicians to get larger samples more consistently, reducing the amount of time, money and patient discomfort associated with the procedure.

The Celero device's features, particularly its trocar tip and ability to pre-fire the inner cannula outside the breast, make it particularly useful when a lesion is located in a sensitive or hard to reach area, such as the axilla or near the nipple, implants or the chest wall. Anecdotal evidence suggests this benefit may increase the number of women who can avoid surgery and opt for a minimally invasive biopsy procedure to diagnose breast lesions.

References

- 1 Cassano E, Urban LABD, Pizzamiglio M, et al. Ultrasound-guided vacuum-assisted core breast biopsy: experience with 406 cases. *Breast Cancer Res Treat.* Vol 102, 2007, pp 103-110.
 - 2 Bassett LW, Mahoney MC, Apple SK. Interventional breast imaging: current procedure and assessing for concordance with pathology. *Radiologic Clinics of North America.* Vol. 45, 2007, pp 881-894.
 - 3 Parker SH, Jobe WE, Dennis MA, et al. US-guided automated large-core breast biopsy. *Radiology.* Vol. 187, May 1993, pp 507-511.
 - 4 Fishman JE, Milikowski C, Ramsinghani R, et al. US-guided core needle biopsy of the breast: how many specimens are necessary? *Radiology.* Vol. 226,, March 2003, pp 779-782.
 - 5 Murta de Lucena CE, Santos Jr. JL, Lima Resende CE, et al. Ultrasound-guided core needle biopsy of breast masses: how many cores are necessary to diagnose cancer? *Journal of Clinical Ultrasound.* Vol. 35, Sept 2007, 363-366.
 - 6 Sauer G, Deissler H, Strunz K, et al. Ultrasound-guided large-core needle biopsies of breast lesions: analysis of 962 cases to determine the number of samples for reliable tumour classification. *British Journal of Cancer.* Vol. 92, 2005, pp 231-235.
 - 7 Parker SH, Burbank F, Jackman RJ, et al. Percutaneous large-core breast biopsy: a multi-institutional study. *Radiology.* Vol. 193, 1994, pp 359-364.
 - 8 Data on file at Hologic, Inc.
 - 9 Sohn, V, Arthurs Z, Herbert G, et al. Atypical ductal hyperplasia: improved accuracy with the 11-gauge vacuum-assisted versus the 14-gauge core biopsy needle. *Annals of Surgical Oncology.* Vol. 14, 2007, 2497-2501.
- Brian S. Englander, M.D. is Director of Imaging at the Integrated Breast Center of Pennsylvania Hospital, Division Chief of the Women's Imaging Center, and Clinical Assistant Professor at the Hospital of the University of Pennsylvania.*